



# Preliminary results of autologous adipose-derived stem cells in early knee osteoarthritis: identification of a subpopulation with greater response

Alfredo Schiavone Panni<sup>1</sup> & Michele Vasso<sup>1</sup> & Adriano Braile<sup>1</sup> & Giuseppe Toro<sup>1</sup> & Annalisa De Cicco<sup>1</sup> & Davide Viggiano<sup>2</sup> & Federica Lepore<sup>1</sup>

Received: 12 September 2018 / Accepted: 21 September 2018

\* SICOT aisbl 2018

## Abstract

**Purpose** The purpose of this study was to report the clinical and functional results of a series of patients with early knee osteoarthritis (KOA) treated with the intra-articular injection of autologous adipose-derived stem cells (aASCs) plus arthroscopic debridement. The hypothesis was that protocol would significantly improve the clinical and functional outcomes in patients with early KOA.

**Methods** Fifty-two patients with early KOA, who received arthroscopic debridement followed by percutaneous injection of aASCs, were enrolled into the study and retrospectively analyzed with an average follow-up of 15.3 (range, 6 to 24) months. Patients were assessed through the IKS knee and function scores and VAS pain scale.

**Results** The mean IKS knee score improved from 37.4 (range, 14 to 79) points pre-operatively to 62.6 (range, 27 to 95) points at the latest follow-up ( $p < 0.01$ ). The mean IKS function score improved from 57.2 (range, 25 to 100) points pre-operatively to 83.0 (range, 35 to 100) points at the latest follow-up ( $p < 0.01$ ). The mean VAS score decreased from 8.5 (range, 3 to 10) pre-operatively to 5.1 (range, 0 to 8) at the latest follow-up ( $p < 0.01$ ). Additionally, patients with a pre-operative VAS score greater than 8 were found to show greater clinical and functional benefits compared with patients with VAS score lower than 8.

**Conclusions** The knee injection of aASCs associated to arthroscopic debridement increased significantly the clinical and functional scores in patients with early KOA at a mid-term follow-up, especially those with higher pre-operative VAS scores.

**Keywords** Adipose-derived stem cells · Fat transfer · Lipogems · Arthroscopic debridement · Knee osteoarthritis

## Introduction

The management of the early knee osteoarthritis (KOA) is much debated since conservative treatment is often ineffective while replacement surgery is premature [1]. Options such as knee arthroscopic debridement, hyaluronic acid with or without corticosteroid injections, and platelet rich plasma (PRP) injection have shown a limited therapeutic reach [2–4].

Intra-articular cell therapies have recently emerged as a method for managing early stages (mild to moderate) of KOA. Mesenchymal stem cells (MSCs) have been investigated in recent years for various regenerative purposes. Biological effects of MSCs are mediated by the secretion of molecules that inhibit ischemia-caused apoptosis and inhibit scar formations, stimulate angiogenesis and vessel stability, and stimulate the mitosis of tissue-intrinsic progenitors [5]. These effects have been proven in orthopaedic clinical practice for the purpose of knee ligament reconstruction and osteoarthritic cartilage treatment [6, 7]. Autologous adipose-derived stem cells (aASCs) have recently attracted attention, especially in the context of cartilage regeneration [8]. Adipose tissue is nowadays considered the most promising due to its abundance, ease of access, and the simplicity of the isolation procedure; moreover, adipose tissue contains a concentration of MSCs greater than bone marrow [1, 7]. Recently, it has been reported how intra-articular injection of autologous

\* Giuseppe Toro  
giusep.toro@gmail.com

<sup>1</sup> Multidisciplinary Department of Medico-Surgical and Dentistry Specialties, University of the Campania BLuigi Vanvitelli<sup>A</sup>, Via L. De Crecchio 4, 80138 Naples, Italy

<sup>2</sup> Department of Medical, Surgical, Neurological, Metabolic and Geriatrics Sciences, University of the Campania BLuigi Vanvitelli<sup>A</sup>, Naples, Italy

microfragmented adipose tissue in patients with KOA increased glycosaminoglycan content in hyaline cartilage, which was in line with observed improved VAS scores and clinical results [1].

The first reports on the use of aASCs in the treatment of KOA have shown promising clinical results [8]. Anyway, many of these studies have utilized aASCs either culture-expanded or obtained by mechanical or enzymatic treatment which involve large number of processing steps, high economic burden, and restrictions associated with cell expansion and extensive manipulation [1]. Moreover, some studies published have used a tissue engineering approach with or without biological adjuvants, involving the use of scaffolds, cells, and growth factors in any combination [8], whereas other studies have used the aASCs knee inoculation as a unique procedure [9]. Finally, most of the studies have utilized aASCs for the treatment of all the grades of KOA therefore including patients with severe knee degeneration that could have confounded final outcomes [7].

The aim of this study was to therefore to report the clinical and functional results of a series of patients with early KOA (grades 0 to II according to the classification of Kellgren-Lawrence [10]) treated with the intra-articular injection of aASCs obtained through a commercially available technique that intra-operatively provides microfragmented and minimally manipulated adipose tissue without expansion or enzymatic treatment. In the same surgical time, all the patients underwent to knee arthroscopy to perform chondral shaving/abrasion and/or meniscal regularization. The hypothesis was that the use of aASCs plus knee arthroscopic debridement would significantly improve the clinical and functional results in patients with early KOA.

## Materials and methods

From 2016 to 2018, 65 patients with KOA underwent intra-articular injection of aASCs plus knee arthroscopy. All operations were performed by two surgeons (ASP and MV). The diagnosis of KOA was made following the American College of Rheumatology criteria [11] and according to the classification of Kellgren-Lawrence. Selection criteria were onset of symptoms of the index knee at six or more months ago, and/or failure of the conservative treatment. Contraindications were recent trauma of the symptomatic knee with evident acute involvement of ligaments and/or menisci, infectious joint disease, chondromatosis or villonodular synovitis of the knee, malignancy, pregnancy, and patients on anticoagulant therapy or suffering from thrombocytopenia and/or coagulation disorder. Age and BMI were not considered a factor influencing the decision to use this protocol, although patients older than 80 years were generally excluded from this treatment.

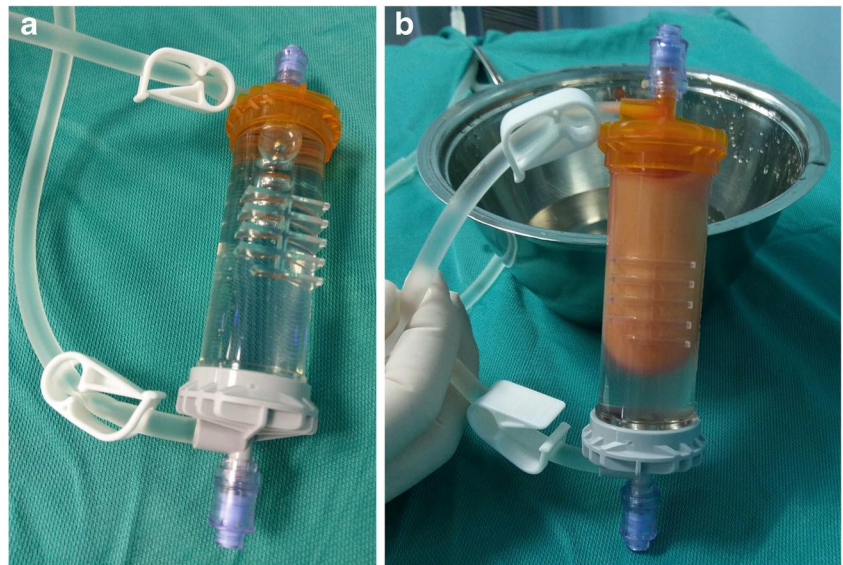
Patients were placed in a supine position; the abdominal skin was treated with betadine first and then chlorhexidine. The minimal invasive surgical procedure included a percutaneous infiltration step. A total of 250 mL of saline solution was mixed with two doses of 7% ropivacaine and half a dose of adrenaline. Of those, 150–180 mL was injected in the abdominal subcutaneous adipose tissue (Fig. 1). Ten to 15 minutes at least were awaited before successive adipose tissue aspiration. Therefore, before fat aspiration, knee arthroscopy was performed to treat any intra-articular lesion. In the aspiration step, a standard lipoaspiration technique was performed, and the harvested fat (40–60 mL) was introduced into Lipogems® ortho kit (Lipogems International SpA, Milan, Italy) (Fig. 2) according to the manufacturer's instructions as previously described [12]. The processed final microfragmented adipose tissue product was transferred to 10 mL syringes (Fig. 3) and injected (10–15 mL) intra-articularly after closing the knee arthroscopy portals with a 3.0 not-resorbable suture (Fig. 4).

Of the total 65 patients who received this protocol, patients (six) with Kellgren-Lawrence KOA grades III or IV, including patients with a severe ( $> 10^\circ$ ) varus or valgus frontal deformity, were excluded from the study. Similarly, patients (three) who received also cartilage procedures such as AMIC [13] or microfracturing techniques for full-thickness chondral lesions were excluded from the study. Finally, patients (two) with a post-traumatic KOA following a previous ligament injury and patients (two) with previous knee surgery were excluded from the study. The 52 remaining patients were enrolled in the study; these 52 patients received only chondral shaving/

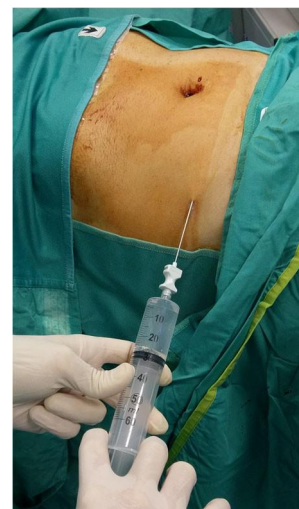

Fig. 1 One hundred fifty to 180 mL of saline solution mixed with ropivacaine and adrenaline are percutaneously injected in the abdominal subcutaneous adipose tissue to expand the spaces inside of the adipose tissue and to facilitate the successive lipoaspiration

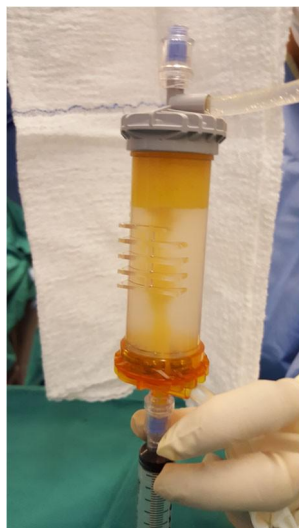**Fig. 2** The Lipogems® ortho kit (a) is filled with the harvested fat (b) to start the process of adipose tissue microfragmentation



abrasion or meniscal regularization though knee arthroscopy. The final 52 patients of the study were retrospectively analyzed with an average follow-up of 15.3 (range, 6 to 24) months. The pre-operative demographic data are listed in Table 1. Patients were assessed pre-operatively and post-operatively through the International Knee Society (IKS) knee and function scores [14] and VAS pain scale. After surgery, patients were clinically evaluated after three, six and 12 months, and every six months thereafter. Before surgery, patients were assessed using a detailed clinical history and an accurate physical examination; at same time, a complete radiographic study, including weight-bearing long-leg AP view radiographs as well as Rosenberg, Merchant and lateral projections, and MRI were performed in all patients. Radiographs and MRI studies were performed to stage the KOA and to

evaluate any intra-articular lesion (ligaments, menisci, cartilage) before surgery.

The ethics committee of the University of Naples (Italy) did not require its approval for the review of patient records or images. All the patients were fully informed of the surgical procedure, treatment duration, and potential complications. All patients signed written informed consent allowing for the surgical procedure. For this type of study, formal consent is not required. Patient demographics and outcomes were described using means and ranges. Improvements relative to the mean IKS and VAS scores analyzed using a Student's *t* test for paired data. Differences in IKS and VAS scores in patients with high (> 8) and low (< 8) at presentation were tested by Student's *t* test for non-paired data. The threshold for statistical significance was defined as  $p < 0.05$ .



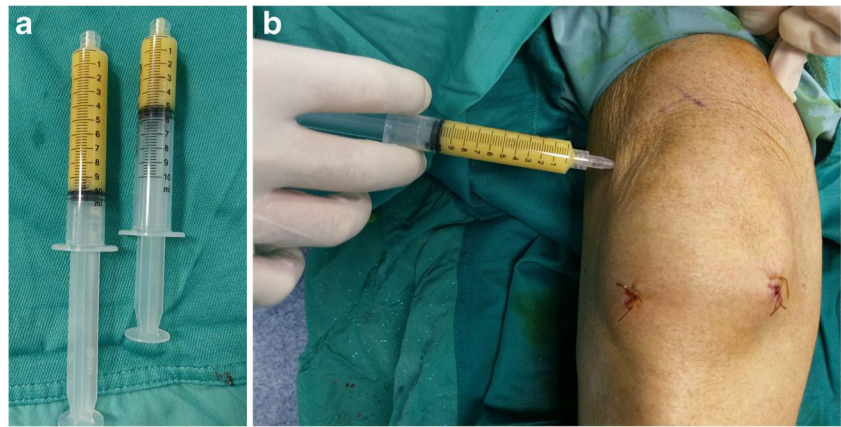
**Fig. 3** The processed final microfragmented adipose tissue product is transferred to 10 mL syringes for the successive articular injection

## Results

The mean IKS knee score improved from 37.4 (range, 14 to 79) points pre-operatively, to 62.6 (range, 27 to 95) points at the latest follow-up ( $p < < 0.01$ , Student's *t* test for paired data). The mean IKS function score improved from 57.2 (range, 25 to 100) points pre-operatively, to 83.0 (range, 35 to 100) points at the latest follow-up ( $p < < 0.01$ , Student's *t* test for paired data). The mean VAS score decreased from 8.5 (range, 3 to 10) pre-operatively, to 5.1 (range, 0 to 8) at the latest follow-up ( $p < < 0.01$ , Student's *t* test for paired data). These data are summarized in Table 2. Overall, the improvement of IKS and VAS scores was not significantly affected by age, BMI, and grade of KOA, as assessed by multiple correlation analysis (all correlations between percent improvement in IKS scores, VAS scores and age, BMI, KOA grade were not significant).



**Fig. 4** The final adipose product (10–15 mL) (✚) is injected intra-articularly after closing the knee arthroscopy portals (✚)



Additionally, patients with a preoperative VAS score higher than 8 were found to show significant greater benefit in terms of percent improvement in IKS knee and function scores and VAS score (Table 3).

Of the total 52 patients, 50 (96.2%) patients were satisfied of outcomes and reported improvements in knee function and/or pain. In particular, 32 (61.5%) patients achieved complete or near-complete function recovery and/or pain relief considering the procedure as excellent, and 18 (34.6%) patients achieved a satisfying function recovery and/or pain reduction considering the procedure as good. Two (3.9%) patients reported only a slight reduction of the pain and were not able to recover a complete ROM, considering the procedure as fair or poor.

Adverse events were recognized only as related to harvesting procedure. Three patients developed a transitory haematoma of the abdominal region that did not influence the post-operative knee recovery. Neither infections nor neurovascular complications developed. A relative reduction of analgesics consumption in the post-operative period was noted, although not statistically investigated.

**Table 1** The demographic data

Total No.	52 patients
Age (year), mean (range)	67.3 (37–78)
Gender	
Male	22 patients
Female	30 patients
KOA stage (Kellgren-Lawrence)	
Grade 0	11 knees
Grade 1	19 knees
Grade 2	22 knees
Side	
Right	32 knees
Left	20 knees
BMI (kg/m <sup>2</sup> ), mean (range)	28.1 (21–34)
Follow-up (months), mean (range)	15.3 (6–24)

## Discussion

The most important finding of this study was that percutaneous injection of aASCs following knee arthroscopy (for chondral shaving/abrasion and/or meniscal regularization) increased significantly the clinical and functional scores in patients with early KOA at a mid-term follow-up. There were no treatment-related adverse events with the regard of the knee procedure. Furthermore, IKS and VAS scores were not significantly affected by age, BMI, and grade of KOA, although patients with grade II KOA and/or obese patients seemed to show lower outcomes. At the latest follow-up, 50 (96.2%) patients expressed satisfaction with outcomes and reported improvements with respect to knee function and/or pain, considering the procedure received as excellent (61.5% of the patients) or good (34.6% of the patients). Only two (3.9%) patients reported dissatisfaction due to an uncomplete recovery of the knee function with only slight pain reduction, both those patients presented a grade II KOA. It is interesting to note how in this study only 27 (51.9%) on 52 patients described a complete remission of the knee pain, whereas 44 (84.6%) of the patients reported a complete or near-complete recovery of the knee functionality. At the same time, in this study, the decrease of the VAS scores was not conspicuous (from 8.5 points pre-operatively to 5.1 at the latest follow-up) (Table 2). This could be partially explained to the primary beneficial mechanical effect of the fat transfer due to its large lubricating capacity, with consequent immediate restoration of the knee motion and function. The primitive mechanical effect of the fat transfer could also explain the higher clinical and functional benefits of the procedure observed in the patients

**Table 2** Mean IKS knee and function and VAS scores

	Preoperatively	Latest follow-up	<i>p</i> value
Mean IKS knee (points)	37.4 (14–79)	62.6 (27–95)	<<0.01
Mean IKS function (points)	57.2 (25–100)	83.0 (35–100)	<<0.01
VAS (points)	8.5 (3–10)	5.1 (0–8)	<<0.01

**Table 3** Percent improvement of IKS knee and function and VAS scores in patients presenting with high or low pain (data represent mean  $\pm$  SEM)

	VAS at presentation < 8	VAS at presentation $\geq$ 8	<i>p</i> value
Improvement in IKS knee (% overbasal)	26 $\pm$ 17%	115 $\pm$ 22%	0.005
Improvement in IKS function (% overbasal)	22 $\pm$ 18%	64 $\pm$ 10%	0.05
Improvement in VAS (% over basal)	4 $\pm$ 15%	44 $\pm$ 4%	0.02

with pre-operative VAS score greater than 8 (Table 3). On the other hand, the initial absence of the secondary biological effect of the aASCc inoculation (in terms of cartilage regeneration), with consequent persistence of knee synovitis due to the cartilage degeneration, associated to a possible acute inflammatory response to the adipose-tissue injection [7, 9] could explain the lack of large pain reduction in the first post-operative period, especially in the patients with pre-operative lower VAS scores. The surgeon could and should take into account this possibility and therefore inform the patient pre-operatively.

Anyway, in this study, the intra-articular injection of aASCs plus arthroscopic debridement significantly increased the overall mid-term outcomes of patients with early KOA. In our department, knee arthroscopy was always associated to the percutaneous fat transfer in order to treat any intra-articular lesion and therefore favour the possible future cartilage regeneration potentially induced by the aASCs. In a recent meta-analysis including 18 clinical trials on the efficacy of MSCs (including aASCs, bone marrow-derived MSCs, synovial-derived MSCs, and peripheral blood-derived MSCs) in treating patients with KOA, Cui et al. [15] have extrapolated that patients with arthroscopic debridement and/or lower degrees of Kellgren-Lawrence KOA achieved higher outcomes. Most of the authors have analyzed the outcomes of the articular injection of aASCs performed as unique procedure, often using this technique in all the grades (0 to IV) of the KOA, therefore reporting contradictory or conflicting results. Adriani et al. [9] reviewed 30 patients, who received an autologous percutaneous fat injection for the treatment of KOA. All patients reported improvements with respect to pain: average VAS decreased from 7.7 pre-operatively, to 4.3 at three month follow-up; a slight deterioration (5.0) was evidenced at one year. Similarly, WOMAC score passed from 89.9 pre-operatively, to 66.3 at one month, 68.6 at three months, and 73.2 at one year. Finally, four patients (13.3%) reported only a slight benefit but were not able to recover a complete ROM, while two patients (6.6%) with a grade III KOA did not obtain any benefit in regard to pain and functional recovery. Pers et al. [7] treated 18 consecutive patients

with severe (grades III and IV) KOA with a single intra-articular injection of autologous ASCs. The study design consisted of three consecutive cohorts (six patients each) with dose escalation: low dose ( $2 \times 10^6$  cells), medium dose ( $10 \times 10^6$ ), and high dose ( $50 \times 10^6$ ). The follow-up was of six months. Although improvement for all clinical outcome parameters (pain, function, and mobility) regardless of the injected dose was observed, statistical significance was detected only for patients treated with the low dose. Additionally, one (5.5%) patient with persistent joint swelling and knee pain underwent TKA surgery six months after the index procedure. Similarly, Jo et al. [16] treated 18 patients with KOA who were grouped according to low-, medium-, and high-dose of aASCs received.

The follow-up was of two years. Although improvement for all clinical, functional and VAS scores in all groups of patients, statistical significance was found mainly in the high-dose group.

As above mentioned, some authors have associated the use of the aASCs to a tissue engineering approach with or without other biological adjuvants, involving the use of scaffolds, cells, and growth factors in any combination, so to confound the real effectiveness of the aASCs [1, 8]. In a recent systematic review on 16 studies, Hurley et al. [8] reported overall favourable clinical outcomes with minimal complications in the treatment of KOA with the use of aASCs. Anyway, the authors concluded that caution should be taken to interpret the outcomes of their study. That systematic review demonstrated the variability in both the data collected and the use of biological adjuvants between studies, thereby limiting proper cross-study comparisons and potentially confounding the real effects of aASCs. In fact, the majority of the studies evaluated (12/16 studies) used an adjunctive procedure. These studies utilized either PRP (7/16) or fibrin (4/16), with one study comparing both biologic adjuncts. It is well-recognized how PRP contains growth factors that increase chondrocyte viability and differentiation, as well as the synthetic capacity of MSCs, which may prove beneficial in cartilage repair [17]. At the same time, both PRP and fibrin can act as a scaffold and may enhance aASCs adherence to cartilage lesions and promote their proliferation [18]. The application of either PRP or fibrin could confound the effects of aASCs in KOA; therefore, the advantages of aASCs beyond the use of these adjuncts could be not determined from their review. In three patients with grade III KOA, Pak et al. [19] associated the percutaneous injection of aASCs to an homogenized extracellular matrix (as scaffold) in the form of adipose stromal vascular fraction, in conjunction with hyaluronic acid and PRP activated by calcium chloride. All patients' MRI data showed cartilage-like tissue regeneration, whereas the measured physical therapy outcomes in terms of ROM, subjective pain, and functional status were all improved.

The main limitation of this study is that a non-randomized case-series was presented. Fifty-two patients with early (grades 0 to II) KOA undergone percutaneous injection of

aASCs following an arthroscopic debridement were included in a retrospective study, but results were not compared with any control group of patients treated through only an arthroscopic debridement. Anyway, it is universally recognized how arthroscopic debridement alone is quite ineffective in treating symptoms of early KOA [20, 21]; therefore, the assumption was taken that arthroscopic procedure for chondral shaving/abrasion and/or meniscal regularization in KOA could not confound the real effectiveness of the aASCs. Exactly for that reason, patients with post-traumatic and/or grades III or IV KOA, patients receiving cartilage procedures such as AMIC or microfracturing, and patients with previous knee surgery, were excluded from this study. Additionally, one could object that in some patients arthroscopic meniscal regularization could have improved symptoms instead of aASCs transfer. Anyway, all the patients in whom the meniscal regularization was performed presented only degenerative meniscal tears whose arthroscopic treatment effectiveness is still highly controversial [22]; patients with recent trauma of the symptomatic knee and evident acute involvement of meniscus were originally excluded to receive this treatment protocol.

At the same, any control group of patients treated with aASCs knee inoculation alone without arthroscopy was not compared, since that, as above mentioned, the results provided by the fat transfer used as unique procedure had conflicting results in many other studies [7, 9, 15, 16]. Another important limitation of this study was that the mean follow-up (15.3 months) was quite short, although no deterioration of the clinical and functional results was appreciated over time, even in patients with longer follow-ups (2 years). Another limitation was that potential biological effect of the aASCs was not evaluated, nor through MRI nor through an arthroscopic second-look. In that regard, no patient asked for an additional surgical treatment, whereas the authors preferred following the patients just clinically and functionally, not being the pre-operative MRI of the patients with early KOA indicative of important signs of cartilage degeneration.

Despite these limitations, the clinical relevance of this study was, however, that knee injection of aASCs associated to arthroscopic debridement is a safe and effective procedure in increasing significantly the clinical and functional scores in patients with early KOA, although at a mid-term follow-up. These results are clinically much more relevant if we consider how the management of the early KOA could be paradoxically rather challenging since conservative treatment is often ineffective while replacement surgery is absolutely premature. Whereas this study was not designed to demonstrate the efficacy of aASCs or its superiority compared to other therapies, our results identified a category of patients (those with pre-operative VAS > 8) that were more likely to take advantage of aASCs injection.

Obviously, large prospective randomized clinical trials and longer follow-ups are certainly necessary, also to

evaluate the effectiveness of cartilage regeneration secondary to the advocated biologic effect of the inoculation of aASCs. Nowadays, since the first reports, ASCs have always demonstrated safety and efficacy in terms of clinical and functional results in patients with KOA, although different levels of abnormality have been found in the regenerated cartilage for most of the patients [23].

## Conclusion

The knee injection of aASCs associated to arthroscopy (for chondral shaving/abrasion and/or meniscal regularization) increased significantly the clinical and functional scores in patients with early KOA at a mid-term follow-up. Knee improvements were found significantly higher in patients with pre-operative VAS score greater than 8. There were no treatment-related adverse events with the regard of the knee procedure. At the latest follow-up, 96.2% of patients expressed satisfaction and reported good or excellent improvements in function and/or pain. The hope remains that the biological effect of this protocol could positively interfere with the natural history of the KOA.

## Compliance with ethical standards

**Conflict of interest** The authors declare that they have no conflict of interest.

## References

1. Hudetz D, Borić I, Rod E, Jeleč Ž, Radić A, Vrdoljak T, Skelin A, Lauc G, Trbojević-Akmačić I, Plečko M, Polašek O, Primorac D (2017) The effect of intra-articular injection of autologous microfragmented fat tissue on proteoglycan synthesis in patients with knee osteoarthritis. *Genes (Basel)* 13;8(10):270
2. Duymus TM, Mutlu S, Dernek B, Komur B, Aydogmus S, Kesiktas FN (2017) Choice of intra-articular injection in treatment of knee osteoarthritis: platelet-rich plasma, hyaluronic acid or ozone options. *Knee Surg Sports Traumatol Arthrosc* 25:485–492
3. Khoshbin A, Leroux T, Wasserstein D, Marks P, Theodoropoulos J, Ogilvie-Harris D, Gandhi R, Takhar K, Lum G, Chahal J (2013) The efficacy of platelet-rich plasma in the treatment of symptomatic knee osteoarthritis: a systematic review with quantitative synthesis. *Arthroscopy* 29:2037–2048
4. Orchard J, Moen MH (2017) Has reimbursement for knee osteoarthritis treatments now reached ‘postfact’ status? *Br J Sports Med* 51: 1510–1511
5. Caplan AI (2015) Adult mesenchymal stem cells: when, where, and how. *Stem Cells Int* 2015:628767. <https://doi.org/10.1155/2015/628767>
6. Cuti T, Antunovic M, Marijanovic I, Ivkovic A, Vukasovic A, Matic I, Pecina M, Hudetz D (2017) Capacity of muscle derived stem cells and pericytes to promote tendon graft integration and ligamentization following anterior cruciate ligament reconstruction. *Int Orthop* 41:1189–1198

7. Pers YM, Rackwitz L, Ferreira R, Pullig O, Delfour C, Barry F, Sensebe L, Casteilla L, Fleury S, Bourin P, Noël D, Canovas F, Cyteval C, Lisignoli G, Schrauth J, Haddad D, Domergue S, Noeth U, Jorgensen C, ADIPOA Consortium (2016) Adipose mesenchymal stromal cell-based therapy for severe osteoarthritis of the knee: a phase I dose-escalation trial. *Stem Cells Transl Med* 5:847–856
8. Hurley ET, Yasui Y, Gianakos AL, Seow D, Shimozone Y, Kerkhoffs GMMJ, Kennedy JG (2018) Limited evidence for adipose-derived stem cell therapy on the treatment of osteoarthritis. *Knee Surg Sports Traumatol Arthrosc*. <https://doi.org/10.1007/s00167-018-4955-x>
9. Adriani E, Moio M, Di Paola B, Salustri W, Alfieri A, Parisi P, Ruggiero M, Borab Z, Carlesimo B (2017) Percutaneous fat transfer to treat knee osteoarthritis symptoms: preliminary results. *Joints* 5:89–92
10. Kijowski R, Blankenbaker D, Stanton P, Fine J, De Smet A (2006) Arthroscopic validation of radiographic grading scales of osteoarthritis of the tibiofemoral joint. *Am J Roentgenol* 187:794–799
11. Misso ML, Pitt VJ, Jones KM, Barnes HN, Piterman L, Green SE (2008) Quality and consistency of clinical practice guidelines for diagnosis and management of osteoarthritis of the hip and knee: a descriptive overview of published guidelines. *Med J Aust* 189:394–399
12. Bianchi F, Maioli M, Leonardi E, Olivi E, Pasquinelli G, Valente S, Mendez AJ, Ricordi C, Raffaini M, Tremolada C, Ventura C (2013) A new nonenzymatic method and device to obtain a fat tissue derivative highly enriched in pericyte-like elements by mild mechanical forces from human lipoaspirates. *Cell Transplant* 22:2063–2077
13. Schiavone Panni A, Del Regno C, Mazzitelli G, D'Apolito R, Corona K, Vasso M (2017) Good clinical results with autologous matrix-induced chondrogenesis (Amic) technique in large knee chondral defects. *Knee Surg Sports Traumatol Arthrosc*. <https://doi.org/10.1007/s00167-017-4503-0>
14. Insall JN, Dorr LD, Scott RD, Scott WN (1989) Rationale of the knee society clinical rating system. *Clin Orthop Relat Res* 248:13–14
15. Cui GH, Wang YY, Li CJ, Shi CH, Wang WS (2016) Efficacy of mesenchymal stem cells in treating patients with osteoarthritis of the knee: a meta-analysis. *Exp Ther Med* 12:3390–3400
16. Jo CH, Chai JW, Jeong EC, Oh S, Shin JS, Shim H, Yoon KS (2017) Intra-articular injection of mesenchymal stem cells for the treatment of osteoarthritis of the knee: a 2-year follow-up study. *Am J Sports Med* 45:2774–2783
17. Krüger JP, Freymannx U, Vetterlein S, Neumann K, Endres M, Kaps C (2013) Bioactive factors in platelet-rich plasma obtained by apheresis. *Transfus Med Hemother* 40:432–440
18. Pak J, Lee JH, Kartolo WA, Lee SH (2016) Cartilage regeneration in human with adipose tissue-derived stem cells: current status in clinical implications. *Biomed Res Int* 2016:4702674. <https://doi.org/10.1155/2016/4702674>
19. Pak J, Lee JH, Park KS, Jeong BC, Lee SH (2016) Regeneration of cartilage in human knee osteoarthritis with autologous adipose tissue-derived stem cells and autologous extracellular matrix. *Biores Open Access* 5:192–200
20. Grieshaber JA, Stanton M, Gambardella R (2016) Debridement of articular cartilage: the natural course. *Sports Med Arthrosc Rev* 24: 56–62
21. Katz JN, Brownlee SA, Jones MH (2014) The role of arthroscopy in the management of knee osteoarthritis. *Best Pract Res Clin Rheumatol* 28:143–156
22. Beaufils P, Becker R, Kopf S, Englund M, Verdonk R, Ollivier M, Seil R (2017) Surgical management of degenerative meniscus lesions: the 2016 ESSKA meniscus consensus. *Knee Surg Sports Traumatol Arthrosc* 25:335–346
23. Gu X, Li C, Yin F, Yang G (2017) Adipose-derived stem cells in articular cartilage regeneration: current concepts and optimization strategies. *Histol Histopathol*. <https://doi.org/10.14670/HH-11-955>